

Transumbilical and Transpubic Breast Augmentation. A Modification of the Gerald Johnson Technique

KIRK R. BRANDOW, MD,* HYDER MUKADAM, MD**

ABSTRACT: During the past two decades, breast augmentation had been almost exclusively performed with silicone gel filled implants which required insertion through large incisions in the breast or axilla. It wasn't until the FDA removed these implants from general use in 1992, that we were forced to use saline filled implants which have the distinct advantage of insertion through a significantly smaller incision. Although scattered reports of remote site breast augmentation existed in the 1980's, the first great innovation in small incision, remote site breast augmentation was developed by Dr. Gerald Johnson in 1991, who placed a saline filled breast implant through an umbilical incision. We have utilized this technique and made a few modifications which we feel have improved the early postoperative results and reduced operative time.

Key Words: *Transumbilical, Transpubic, Saline implants, Reston foam and Breast tunnelor*

INTRODUCTION

Body image and that which a woman perceives as attractive is often influenced by the societal and environmental norms of each culture; yet as our world grows smaller and smaller, the international media network can play an even greater role in creating and manipulating these concepts of beauty. Even South American and Oriental nations who had traditionally revered small breasted women have been influenced by western films and magazines which promote large breasts as the "vogue look" of our international women. This image has been facilitated by the advent of breast augmentation and over the past 30 years has fulfilled the dreams of many women who felt inadequate about their breast size. However, the controversy surrounding silicone breast implants has led to much confusion and emotional anxiety, forcing many to reconsider breast augmentation for fear of the unknown.¹⁻⁵

In the United States, the FDA's decision to remove polyurethane coated implants and restrict silicone im-

plants⁶ has forced surgeons to utilize saline filled implant as the only means of fulfilling the dreams of their patients. However, from this constraint has come creativity and innovation.

In 1991, Dr. Gerald Johnson combined the improved versatility of these saline filled implants with endoscopy and tissue expansion to perform the first transumbilical breast augmentation using saline filled breast implants.⁷ His instrumentation and training programs have brought us one step further in restoring patients' confidence in breast augmentation by offering them a safe procedure resulting in a virtually undetectable umbilical incision with a natural looking, scar free breast.

Presented here is a slight modification of the Johnson technique. We utilize a rigid tunneling device, (Byron Medical, Tucson, Arizona) similar to a vein stripper, to bluntly create a subglandular breast pocket, bypassing the need for large mammascopes and tissue expanders. This reduces operative time and expense while decreasing the size of umbilical and suprapubic incisions. Additionally, the early postoperative results appear to be more natural with the creation of a larger subglandular pocket while the use of Reston foam tape (3M Medical-Surgical Division, St. Paul, MN) significantly decreases postoperative pain and bruising both in the breast and abdomen.

Department of Aesthetic & Restorative Surgery Graduate Hospital, Philadelphia, PA 19146.

**Chief of Body Contouring Surgery.*

***Fellow in Training.*

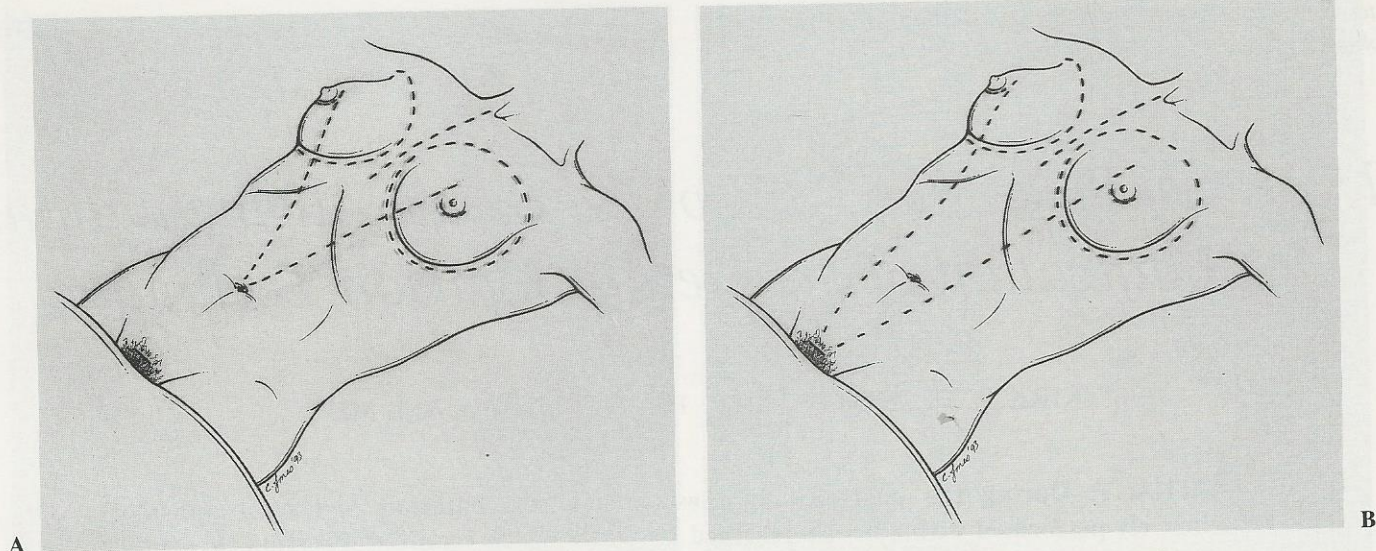


Figure 1A & 1B. Preoperative markings using tangential line from umbilicus or pubis to inner nipple.

PREOPERATIVE PLANNING

Patients are thoroughly advised of the surgical options, complications, and incisions available for breast augmentation. Provided their needs and outcomes can be met safely and successfully through either a transumbilical or a transpubic incision, surgery is scheduled on an outpatient basis under general anesthesia. All patients are informed that technical problems may occur during the procedure which would necessitate conversion to a periareolar incision and they give consent to this alternative prior to the procedure.

Use of the breast tunnelor is less traumatic and simpler when performed through the umbilicus and this surgeon's incision of choice. However, if a previous suprapubic or midline abdominal scar exists or augmentation will be combined with a secondary procedure such as miniabdominoplasty, etc., one should consider using that incision to avoid an additional scar.

TECHNIQUE

The breasts are marked per the Johnson Procedure's routine with a tangential line from either the umbilicus or pubis drawn to the inner nipple (Fig. 1A & 1B). The patient presented here will undergo transumbilical augmentation. After the patient has been prepped and draped in the usual sterile fashion, a sterile Q-tip soaked in betadine is used to sterilize the umbilical area. The upper abdomen to the level of the breast is then covered with a steridrape to minimize skin contamination at the entry site (Fig. 2).

A semilunar incision from 10 o'clock and measuring 2–3 cm is made in the lower ridge of the umbilicus with a #11 blade. Dissection is taken down to the rectus fascia (Fig. 3) and infiltration of a solution of 200 cc of normal saline with 50 cc of 1% xylocaine with epinephrine 1:100,000 is infiltrated along the proposed tunnel and subglandular

space with a 1 mm diameter, 40 cm length, multiport infiltrating cannula (Fig. 4). We then wait for 7–10 minutes to allow for vasoconstriction. If the umbilicus is quite small, a "Z" shaped incision may be made to produce an increase in length (see patient photo, case 1G).

A supraumbilical pocket measuring 4 × 4 cms is bluntly created with a metzenbaum scissors in the avascular plane of the rectus sheath to allow the breast tunnelor and subsequent implant to easily pass through the entrance site. If this plane is not identified, local bleeding and moderate resistance may be experienced when attempting to pass the tunnelor. During this dissection and manipulation, skin hooks are used to avoid unnecessary periumbilical skin suffering which can lead to noticeable scarring.

The rigid breast tunnelor is passed up to the inferior border of the breast envelope. In a maneuver outlined by Dr. Gerald Johnson, the opposite hand elevates the breasts and the tunnelor is pushed into the subglandular space

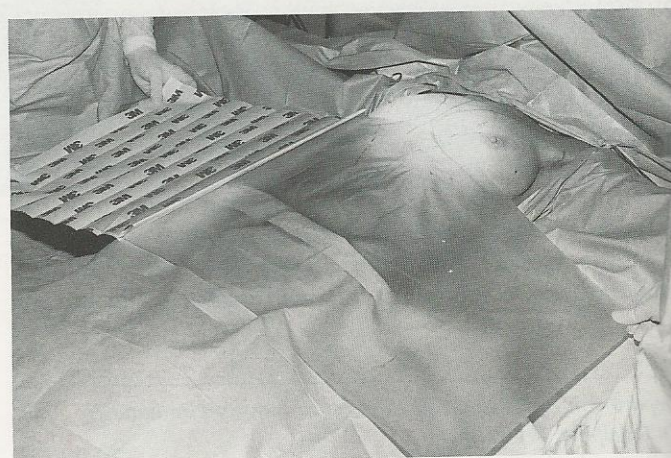


Figure 2. Steridrape used to cover upper abdomen.

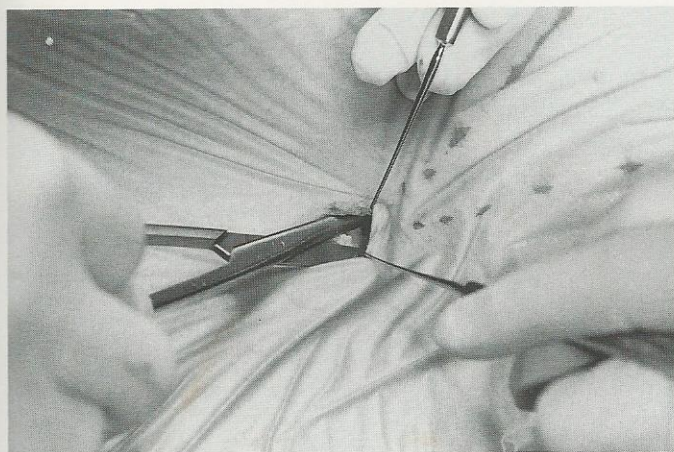


Figure 3. Dissection with metzenbaum scissors to rectus fascia.

(Figs. 5 & 6). At this level, one meets some resistance and care must be taken not to enter too superficially into the glandular tissue or too deeply into the muscle, in order to avoid defects in the inferior pole of the breast as well as bleeding. Once a pop is felt and dissection proceeds easily (Fig. 7), one is in the correct subglandular, fascial plane. A generous pocket is then created to the outer limits of the preoperative markings (Fig. 8). Two hands with moderate force are often necessary to dissect the inner (from 9 o'clock–7 o'clock) and outer (from 3 o'clock–5 o'clock) edges which are the most adherent areas encountered during the dissection.

After the pocket is complete, the tunnelor is pulled backward along the tangential line drawn from the line drawn from the inner nipple of the breast to the umbilicus to create a 3 cm wide corridor so the implant can comfortably slide once it is inserted through the umbilical incision.

A rigid, zero degree endoscope (40 cm) attached to a video monitor is inserted into the pockets to check for placement and bleeding. To facilitate viewing, the breast is

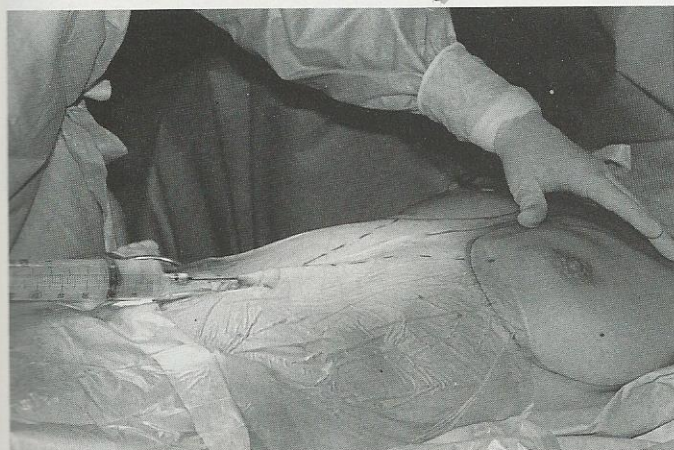


Figure 4. Local anesthesia infiltrated along tunnel and in subglandular breast space.

lifted to create a visible cavity (Fig. 9). Generally, the pockets are easily viewed and have virtually no oozing.

The author has used both textured, anterior filled saline breast implants (McGhan Manufacturing) and smooth, posterior filled saline breast implants (Mentor Company), but has found the insertion of the smooth implants easier due to their ability to slide into the pocket and be rolled into a smaller diameter than the bulkier textured implants. All gloves are changed and then hands and implants washed in a solution of Bacitracin 50,000 U & Polymyxin 500,000 U in 1000 cc normal saline.

The standard tubing accompanying the implants is often not long enough to reach the pocket. In our first few cases, we had to tie the two standard fill tubes together in order to have enough length to reach from the umbilicus to the breast. Now, we use an extended, autoclavable fill tube (created by Mentor Company) which is attached to a hanging bag of injectable saline to form a closed system. The specially designed extension not only avoids potential separation of the tied tubes during insertion, but also and more importantly, will create a closed system that will eliminate the potential risk of air-borne contaminants from entering the injectable saline solution, which is often left sitting in an open basin on the scrub nurse's table (Fig. 10).

The expiration dates of the injectable saline solution are checked and recorded in the chart. The implant is then rolled into a double leafed, cigar shaped configuration (Fig. 11) and inserted into the tunnel (Fig. 12). Using my "Inch Worm Technique" (Fig. 13), the implant is gently manipulated into the pocket without needing the dissector which could inadvertently dislodge the fill tube. One must be sure to have created a wide enough tunnel to allow the implant to easily pass and if a problem arises, the implant can be removed and tunnel enlarged. Once the implant is filled to 25 cc more than its' capacity, the fill tube is capped and left in place until the opposite side is completed. The dissector is once again reinserted and final contouring can be done to allow the implants to rest naturally in place (Fig. 14). Once confident of symmetry and before removing the filling tubes, the patient is sat up into a 45° position to be sure of volume and form (Fig. 15). The fill tubes can then be easily removed.

The umbilical incision is closed with 5-0 interrupted Giles type stitches with the breasts and the abdomen covered using Reston foam tape. If any oozing was noted, a Pitanguy type, plaster cast is placed on the breasts for the first 24 hours (Fig. 16). All patients are seen the following day and sutures are removed on the ninth postoperative day. Exercise is resumed in 3 weeks and all patients begin massage in the second postoperative week.

RESULTS

This procedure has been performed on 23 patients for 47 breasts from December, 1993 to June 1994. Twenty transumbilical, one suprapubic, and two combined cases of miniab-

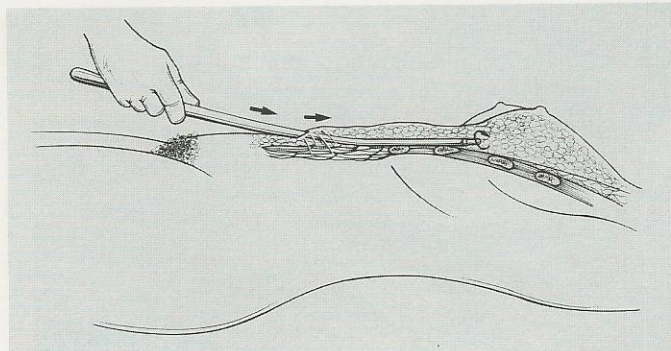
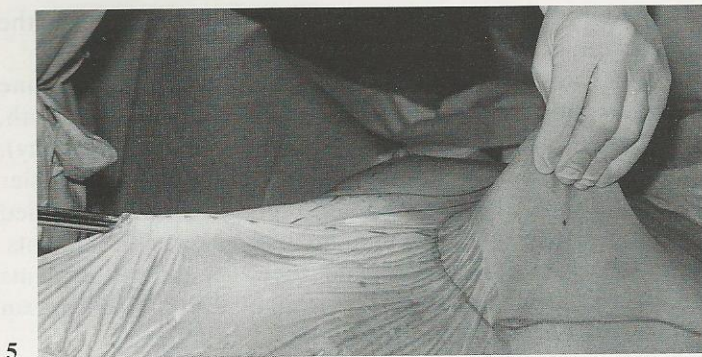

Figure 5 & 6. Breast Tunnelor at base of subgladular space.

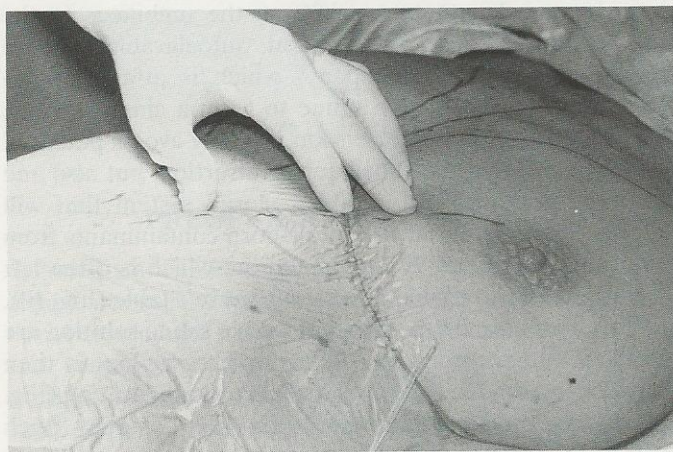


Figure 7. A "PoP" felt with breast tunnelor and entry into subgladular space.

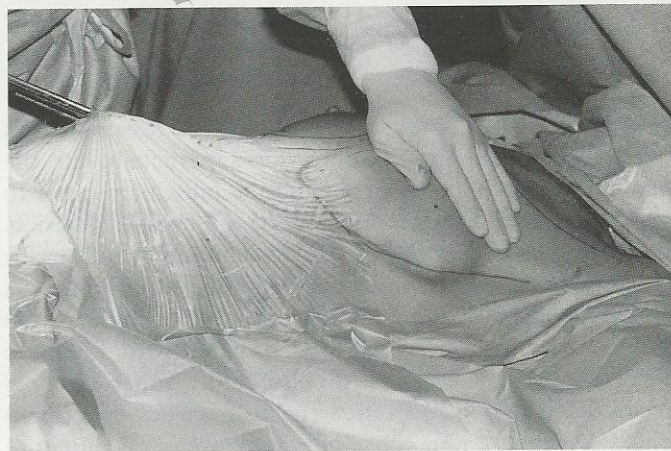

Figure 9. Zero degree endoscope in subgladular pocket.

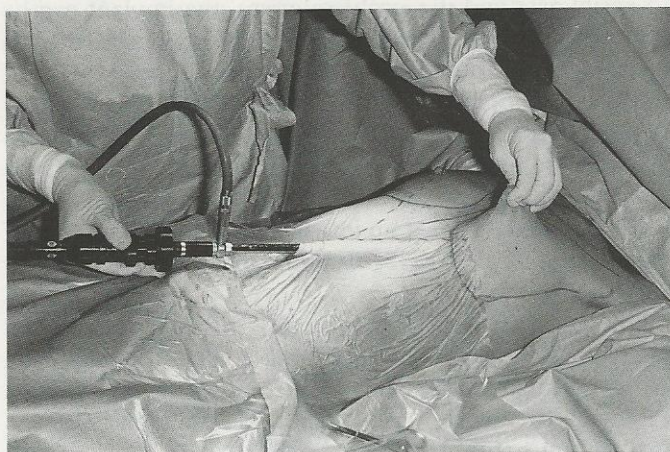


Figure 8. Creation of subgladular pocket.

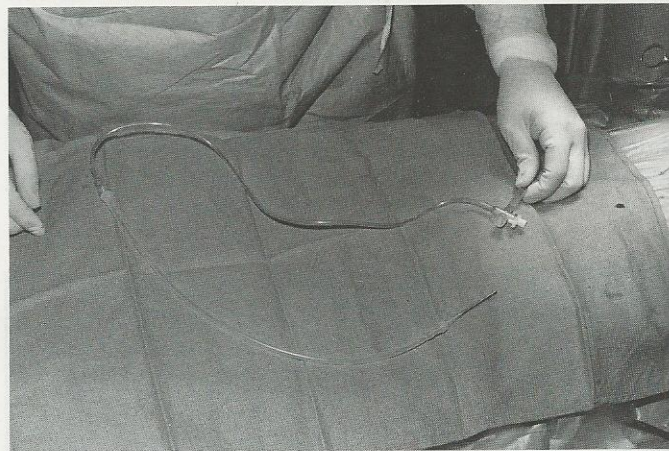


Figure 10. Specially designed, extended tubing measuring 36 cm. Standard tubing is 16 cm.

dominoplasty with transabdominal breast augmentation have been performed. During this period, there have been no instances in which conversion to a periareolar incision was necessary. While performing the third transumbilical case using a textured, anterior filled saline implant, the tubing was dislodged and the implant was sacrificed under

direct vision with an endoscopic allis clamp. For this reason, we always have at least three implants available for each case. Since then, I have switched to a posterior filled, smooth walled implant (Mentor Company) to avoid detection of the anterior valve in thin women and the "rippling effect" occasionally seen with some textured implants over the long term.⁸

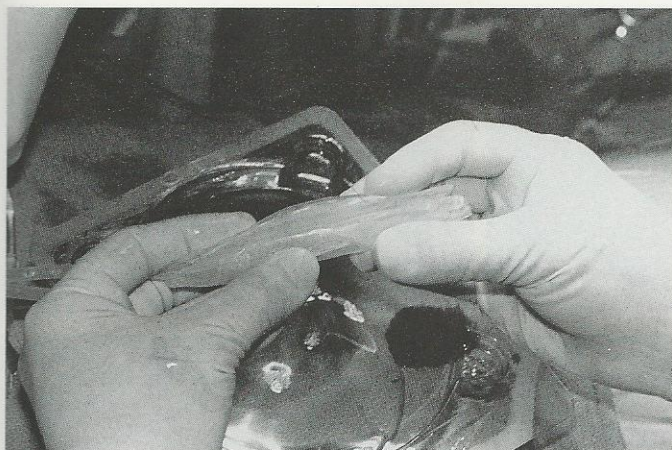


Figure 11. *Cigar shaped implant folded for insertion.*

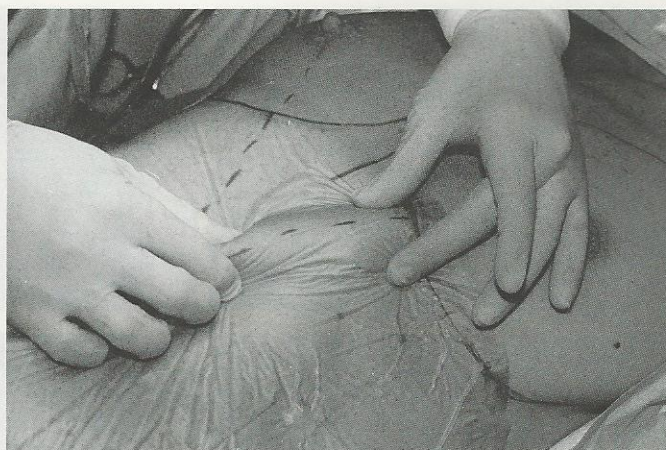


Figure 14. *Dissector is reinserted to complete the pocket.*

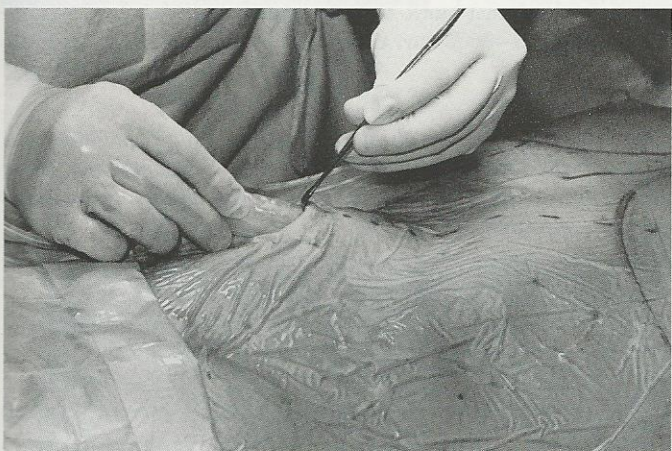

Figure 12. *Insertion of rolled implant into umbilical incision.*

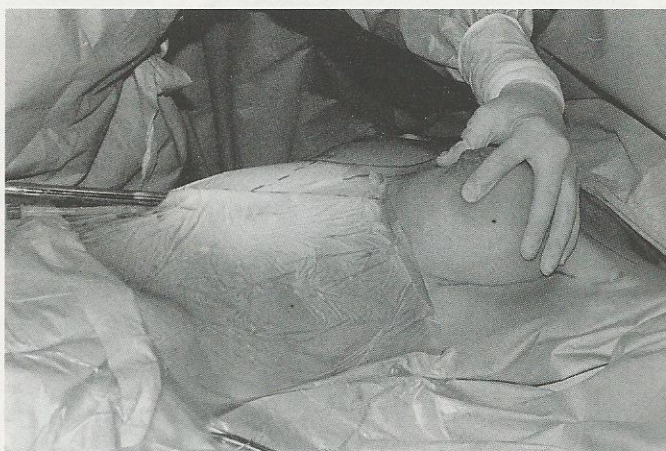


Figure 15. *OR Table elevated to 45 degrees and symmetry of breasts checked.*

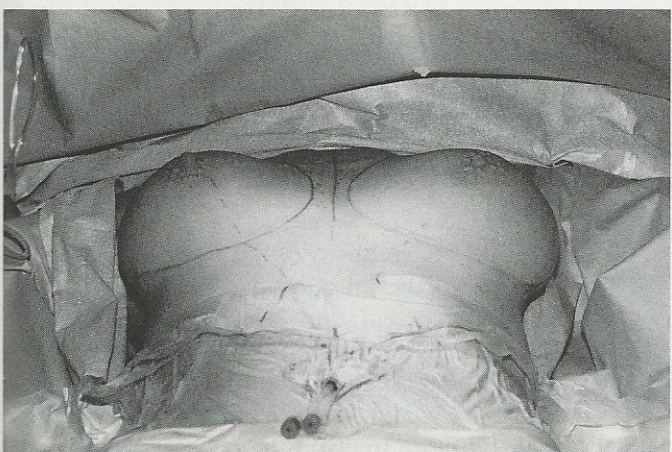
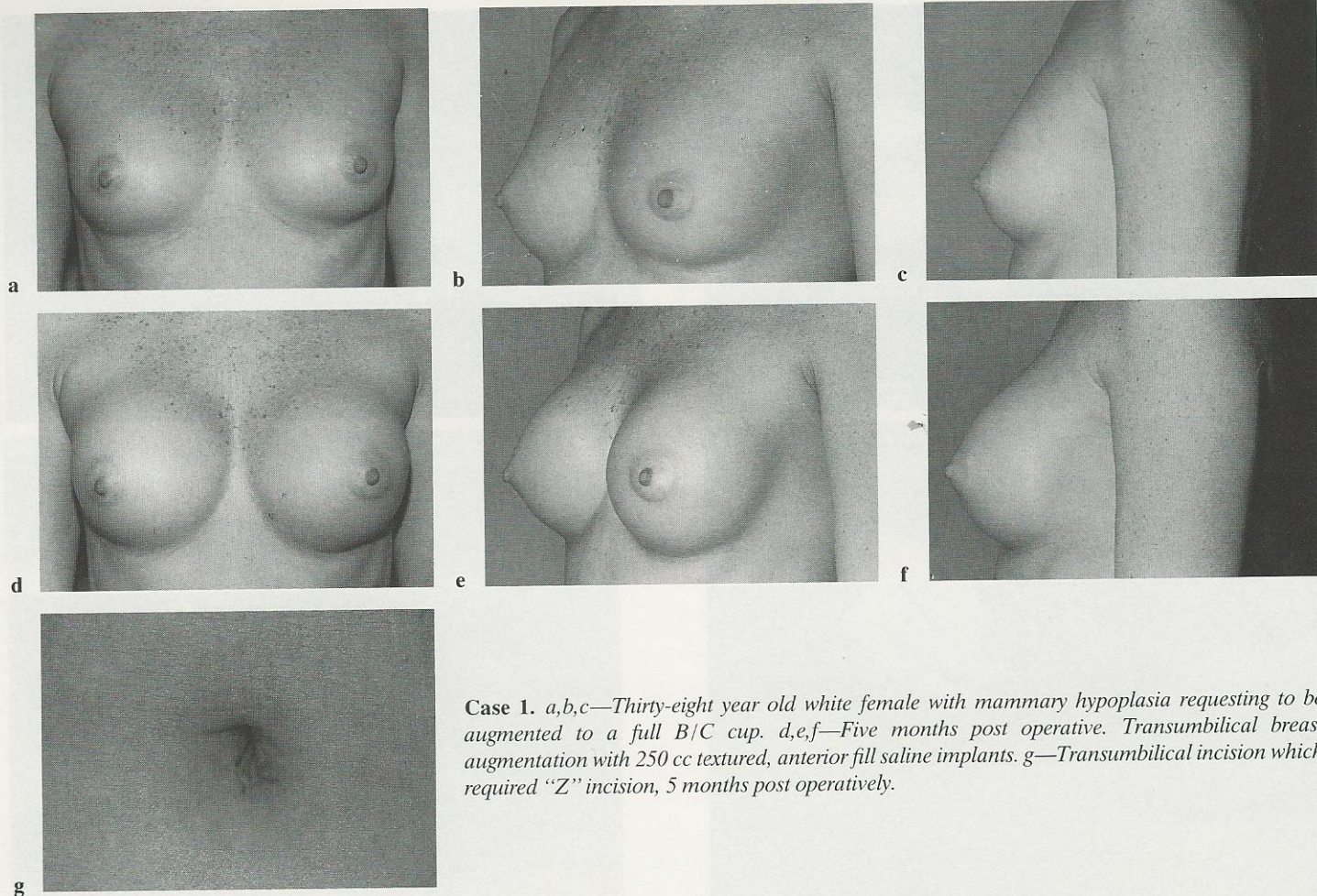


Figure 13. *"Inch Worm" technique for advancement of implant through tunnel into pocket.*

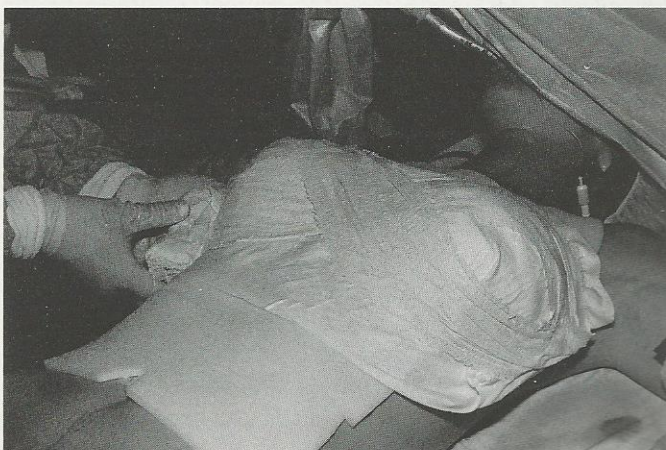

Figure 16. *Plaster cast applied over Reston Foam on breasts.*



Case 1. *a,b,c—Thirty-eight year old white female with mammary hypoplasia requesting to be augmented to a full B/C cup. d,e,f—Five months post operative. Transumbilical breast augmentation with 250 cc textured, anterior fill saline implants. g—Transumbilical incision which required “Z” incision, 5 months post operatively.*

While performing the fifth case, the implant flipped inside the pocket requiring its' removal. During manipulation and attempt to retrieve this implant with an endoscopic allis clamp, sufficient tissue trauma had occurred to produce a mild oozing once the implant was removed and then replaced. Under direct vision with the endoscope, the pocket appeared to be dry enough to close. However, a unilateral postoperative hematoma was identified the following day. The same day, the patient returned to the operating room and interestingly, after rupturing the implant, we inserted a rubber tubing attached to a liposuction machine and were able to extract the implant down the tunnel far enough to atraumatically remove it by hand. The pocket was then washed with 2000 cc of our antibiotic solution until the pocket was clean. Direct visualization with the endoscope did not reveal any further oozing and the implant was replaced.

Theoretically it might be possible to remove a subsequent implant with the tubing attached to a liposuction machine, provided the implant was deflated, without puncturing or potentially weakening the wall of the implant. This would avoid the need to sacrifice an expensive implant if a fill tube dislodged.

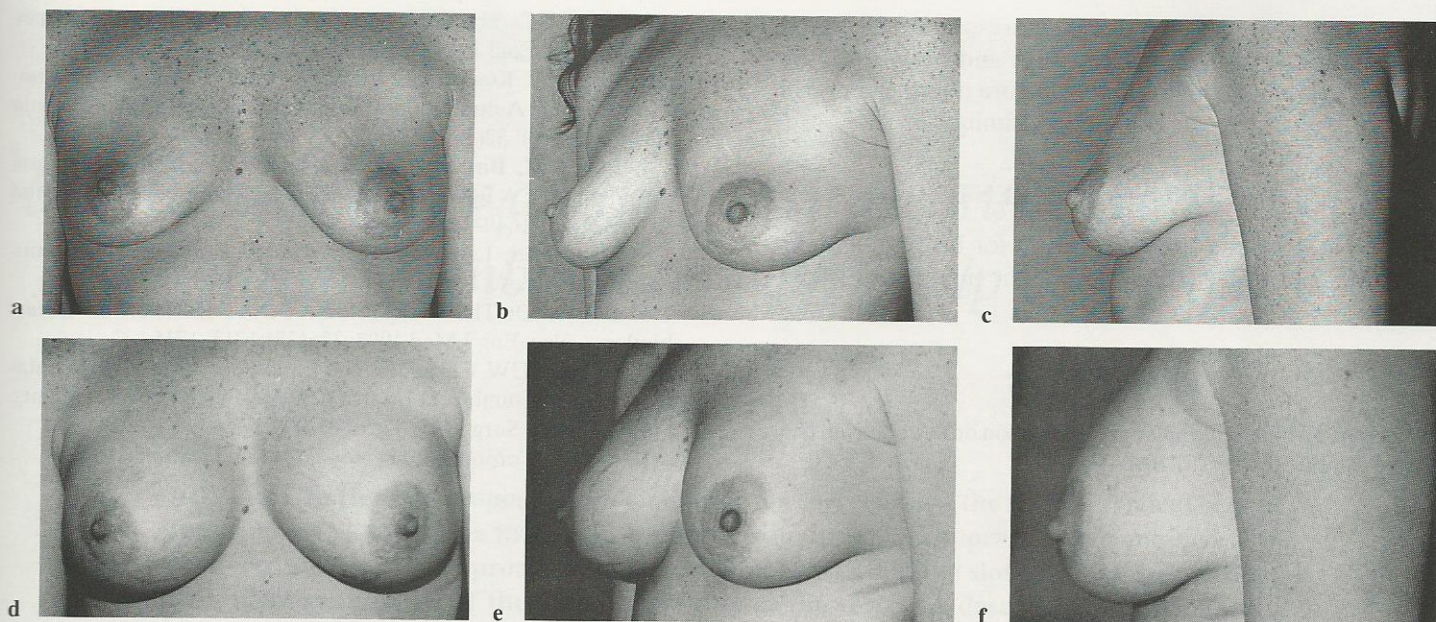
After the fifth case, we have had no further problems and

are able to perform the entire procedure in less than 40 minutes. The long term capsular contracture rate or infection have yet to be seen; however, the early postoperative results and patient satisfaction have been gratifying (clinical cases 1–3).

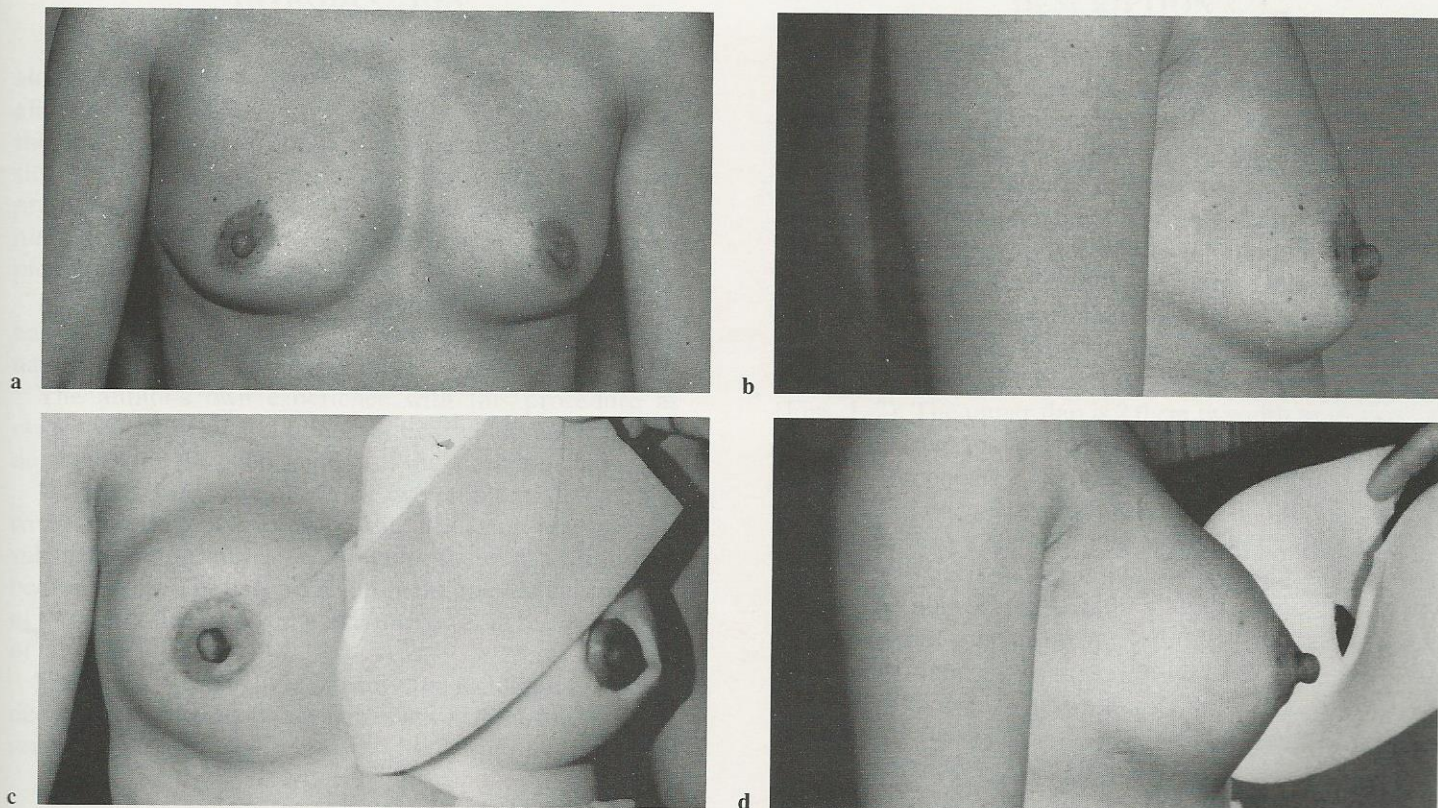
CONCLUSION

The transumbilical and transpubic approach are a tremendous advancement in breast augmentation. Not only does this procedure maintain the breast in its' natural fascial envelope, but also, it avoids a scar on the breast so when a woman who comes to us with insecurities about her breast size will have no footprints to remember us by.

The innovation and creativity of Dr. Gerald Johnson has taken us one step further in reducing the anxiety and fear regarding breast augmentation. The slight modification presented here has allowed us to bypass tissue expansion by creating a generous pocket with a blunt tunnelor so that the early postoperative results would be more natural and the implant would sit more freely in the pocket. Additionally, the entrance site incision is smaller and operative time and expenses have been decreased.



Case 2. *a,b,c*,—Twenty-eight year old white female with mammary hypoplasia, infraumbilical lipodystrophy and rectus sheath diastasis and requested to be augmented to a full B cup. *d,e,f*—Eight weeks post miniabdominoplasty with transabdominal breast augmentation using 225 cc smooth, posterior fill saline implants.



Case 3. *a,b*—Thirty-two year old oriental female with mammary hypoplasia who requested to be augmented to a B cup. *c,d*—Six days post transumbilical breast augmentation with 200 cc smooth, posterior fill saline implants. Reston foam tape is removed from the right breast and right upper abdomen. Note: almost complete absence of ecchymosis and swelling.

Clearly, long term follow-up and more experience regarding the rates of capsular contracture and ptosis resulting from this procedure are necessary before it is deemed to be "better" than the more traditional techniques.

ACKNOWLEDGMENT

We wish to thank David Tourison for his photographic expertise, and Kim McLaughlin for the manuscript preparation.

REFERENCES

1. Angell M: Breast Implants—Protection or Paternalism. *New Engl J Med* 1992; 126(25):1696–1698.
2. Fisher JC: The Silicone Controversy—When will Science Prevail? *New Engl J Med* 1992; 126(25):1696–1698.
3. Peters W, Keystone E, Snow K, et al.: Is There a Relationship Between Autoantibodies and Silicone Gel Implants? *Ann Plast Surg* 1994; 32(1):1–7.
4. Berkel H, Birdsell DC, Jenkins H: Breast Augmentation Mammoplasty: A Risk Factor for Breast Cancer. *New Engl J Med* 1992; 326(25):1649–1653.
5. Fiala TGS, Lee WPA, May JW: Augmentation Mammoplasty: Results of a Patient Survey. 1993; 30(6):503–509.
6. Kessler D: The Basics of the FDA's Decision on Breast Implants. *New Engl J Med* 1992; 326(25):1713–1715.
7. Johnson GW, Christ JE: The Endoscopic Breast Augmentation: The Transumbilical Insertion Saline-Filled Breast Implants. *Plast Reconstr Surg* 1993; 92(5):801–808.
8. Mentor Corporation, Personal Communication, 1992.